

## CORRESPONDENCE

## Emergency Caesarean delivery in a patient with confirmed coronavirus disease 2019 under spinal anaesthesia

Haifa Xia<sup>1,†</sup>, Shuai Zhao<sup>1,†</sup>, Zhouyang Wu<sup>1</sup>, Huilin Luo<sup>2</sup>, Cheng Zhou<sup>3,\*</sup> and Xiangdong Chen<sup>1,\*</sup>

<sup>1</sup>Department of Anaesthesiology, Union Hospital, Tongji Medical College, Huazhong University of Science and Technology, Wuhan 430022, China, <sup>2</sup>Department of Anaesthesiology, Wuhan Red Cross Hospital, Wuhan 430015, China and <sup>3</sup>Laboratory of Anaesthesia & Critical Care Medicine, Translational Neuroscience Center, Department of Anaesthesiology, West China Hospital of Sichuan University, Chengdu, 610041, Sichuan, China

\*Corresponding authors. E-mails: [zhouc@163.com](mailto:zhouc@163.com), [xiangdongchen2013@163.com](mailto:xiangdongchen2013@163.com)

†These authors contributed equally to this study.

**Keywords:** anaesthetic management; Caesarean delivery; COVID-19; SARS-CoV-2; spinal anaesthesia

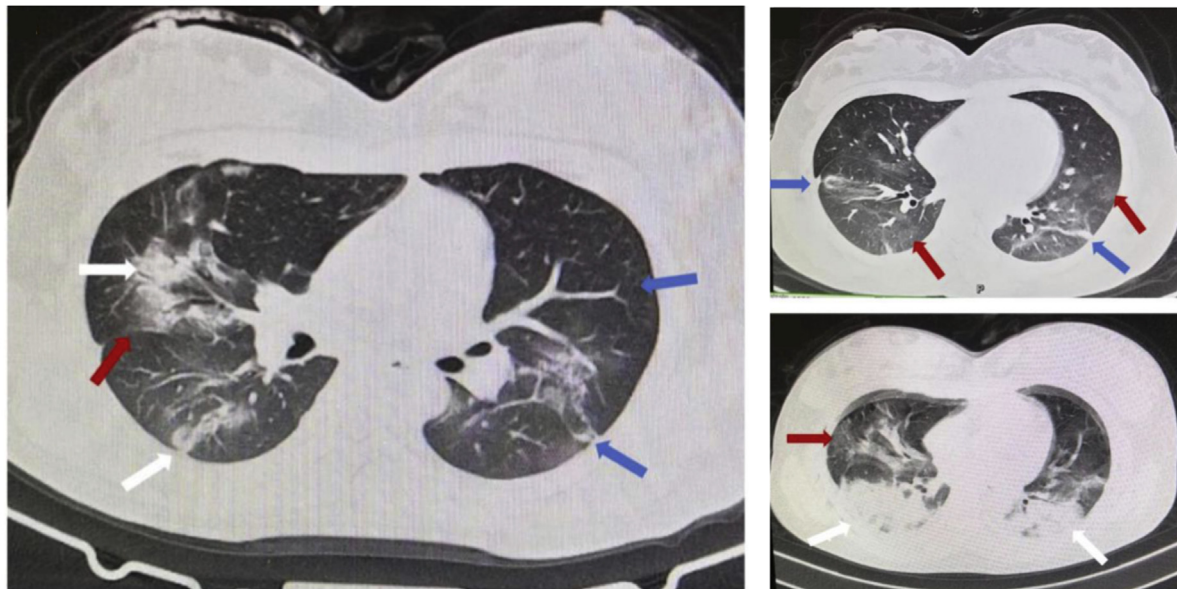
Editor—Wuhan, the core city of central China, has reported an outbreak of atypical pneumonia caused by a 2019 novel coronavirus in late 2019. This coronavirus is officially named severe acute respiratory syndrome coronavirus 2 (SARS-CoV-2).<sup>1,2</sup> There are many pregnant women presenting with coronavirus disease 2019 (COVID-19), which undoubtedly threatens the lives of both mother and baby. Currently, there are no statistics regarding pregnant women infected with COVID-19. A retrospective review has indicated the clinical characteristics of nine pregnant women with COVID-19.<sup>3</sup> However, how anaesthesia was undertaken during delivery is unknown. Here, we report a case of successful spinal anaesthesia in a woman with confirmed COVID-19 who required emergency Caesarean section. Of note, there were 35 cases with confirmed COVID-19 undergoing emergency Caesarean delivery in Wuhan Union Hospital from 23 January, 2020 to 20 February, 2020, with further clinical investigation in progress.

On 20 January, 2020, a 27-yr-old woman with a pregnancy of 36 weeks and 5 days was admitted to Wuhan Red Cross Hospital because of fever. Four days later, the condition of the patient worsened as oxygen saturation was 92–93% whilst breathing ambient air and reduced fetal movement was reported. B-ultrasound revealed that there was little amniotic fluid and intrauterine distress was possible. Considering her physical condition, an emergent Caesarean delivery was decided. Physical examination at admission revealed a body

temperature of 37.9°C, BP of 110/80 mm Hg, HR of 98 beats min<sup>-1</sup>, and ventilatory frequency of 22 bpm. Dry and wet pulmonary rales were observed on bilateral lung auscultation. The laboratory results were haemoglobin 104 g L<sup>-1</sup>, white blood cells 5.31 ( $\times 10^9$  L<sup>-1</sup>), neutrophils 4.48 ( $\times 10^9$  L<sup>-1</sup>), lymphocytes 0.74 g L<sup>-1</sup>, and C-reactive protein 99.6 mg L<sup>-1</sup>, whilst other blood biochemical and coagulation parameters were within normal limits. The SARS-CoV-2 testing was positive in the sample of oropharyngeal swabs by rRT-PCR assay, whereas other viral respiratory pathogens were all negative. Chest CT indicated multiple patchy lung consolidation bilaterally and ground-glasslike opacities around the border, and the subpleural distribution was dominant, which are the typical manifestations of COVID-19 (Fig. 1).<sup>4–6</sup>

SARS-CoV-2 can be transmitted through small droplets from normal breathing, coughing, and sneezing, and by aerosol or fluid from human secretions or discharges.<sup>4,6,7</sup> Third-level measures of medical protection were implemented in the operating theatre immediately after informing the Department of Anaesthesiology, including handwashing clothes, medical standard mask (N95) and disposable surgical cap, medical goggles (or positive-pressure headgear), disposable protective clothing, disposable gloves, and disposable shoe covers.<sup>8</sup> The N95 masks were fit tested to effectively prevent aerosol or fluid secretions.

Perioperative monitoring consisted of five-lead electrocardiography, pulse oximetry, noninvasive BP, and peripheral



**Fig 1.** Chest CT findings of the pregnant woman with confirmed coronavirus disease 2019 showed multiple patchy consolidation of bilateral lung fields and ground-glasslike shadows around the border, with subpleural distribution dominant. White arrows represent patchy consolidation, red arrows represent ground-glasslike shadows, and blue arrows represent interlobular septal thickening.

venous catheterisation. Preoperative examination revealed a body temperature of  $36.8^{\circ}\text{C}$ , HR of  $138\text{ beats min}^{-1}$ , BP of  $141/91\text{ mm Hg}$ , oxygen saturation of 92% whilst breathing ambient air, and wet and dry pulmonary rales. The patient kept coughing whilst lying on her back, and she complained that she was flustered and unwell. Then, she was adjusted to a sitting position and received oxygen at a flow rate of  $5\text{ L min}^{-1}$  via a mask. Based on the symptoms of COVID-19 and her general situation, we chose single-dose spinal anaesthesia. She was positioned in the left-lateral tilt position ( $15^{\circ}$ – $30^{\circ}$ ) and was advised to avoid coughing as much as possible. Subarachnoid puncture was performed at L2–L3 injected with a total of 3.0 ml volume containing glucose 50% (0.5 ml), ropivacaine 1% (1.5 ml), and saline 1.0 ml, followed by an epidural catheter. Once anaesthesia was complete, the patient adjusted to the supine position, and the anaesthesia level was determined as T6. The maternal HR and BP were well controlled, with oxygen saturation of 95–99% with oxygen ( $3\text{ L min}^{-1}$ ) via a face mask. Caesarean section was started 10 min later. The patient coughed frequently during the operation, and her HR was  $>138\text{ beats min}^{-1}$  whilst bleeding was normal ( $\sim 300\text{ ml}$ ). Cough and tachycardia interfered with surgery, and the patient was agitated and dysphoric requiring constant communication. Transient hypotension occurred during the surgery, which was stabilised by i.v. methoxamine 1.5 mg. Ten minutes after skin incision, a male infant weighing 3100 g was delivered with 1 and 5 min Apgar scores of 9–10. The newborn was immediately transferred to a neonatal isolation ward for specialist neonatal treatment to minimise the potential risk of infection.

After delivery, carboprost tromethamine (Hemabate®, Pharmacia & Upjohn Company, Kalamazoo, MI, USA)  $250\text{ }\mu\text{g}$

was administered by i.m. injection of the uterine body. The vital signs of the patient were stable, and she was transferred to the isolation ward. Postoperative analgesia was achieved using epidural patient-controlled analgesia. On the first day after operation, oxygen saturation was 85–89% with nasal catheter oxygen ( $3\text{ L min}^{-1}$ ), and 97–99% on the second day. Cefazolin (2 g daily) was administered for 3 consecutive days from the first postoperative day. On the third day after surgery, the temperature of the mother returned to normal. SARS-CoV-2 was negative in oropharyngeal swabs of the mother and newborn on the third and fifth days after surgery. No medical staff involved in this case was found to be infected with SARS-CoV-2 subsequently.

In conclusion, spinal anaesthesia with appropriate procedures during emergency Caesarean delivery in a patient with confirmed COVID-19 appears safe, although more evidence and cases are needed as information on the anaesthetic care of patients with COVID-19. [9]. Moreover, infants can be delivered free from infection.

### Authors' contributions

Study conception/design: CZ, XC

Data collection: HX, SZ, ZW, HL

Data analysis: HX, SZ, ZW, CZ, XC

Data interpretation: CZ, XC

Drafting of manuscript: HX, SZ, CZ, XC

Revising/final approval of manuscript: all authors

### Declaration of interest

The authors declare that they have no conflicts of interest.

## Funding

National Key Research and Development Project (2018YFC2001802) to XC; National Natural Science Foundation of China (81571075) to XC.

## References

1. Wu A, Peng Y, Huang B, et al. Genome composition and divergence of the novel coronavirus (2019-nCoV) originating in China. *Cell Host Microbe* 2020. <https://doi.org/10.1016/j.chom.2020.02.001>. Advance Access published on February 7
2. Lu R, Zhao X, Li J, et al. Genomic characterisation and epidemiology of 2019 novel coronavirus: implications for virus origins and receptor binding. *Lancet* 2020; **395**: 565–74
3. Chen H, Guo J, Wang C, et al. Clinical characteristics and intrauterine vertical transmission potential of COVID-19 infection in nine pregnant women: a retrospective review of medical records. *Lancet* 2020. [https://doi.org/10.1016/S0140-6736\(20\)30360-3](https://doi.org/10.1016/S0140-6736(20)30360-3). Advance Access published online February 12
4. Huang C, Wang Y, Li X, et al. Clinical features of patients infected with 2019 novel coronavirus in Wuhan, China. *Lancet* 2020. [https://doi.org/10.1016/S0140-6736\(20\)30183-5](https://doi.org/10.1016/S0140-6736(20)30183-5). Advance Access published online January 24
5. Chung M, Bernheim A, Mei X, et al. CT imaging features of 2019 novel coronavirus (2019-nCoV). *Radiology* 2020. <https://doi.org/10.1148/radiol.2020200230>. Advance Access published on February 4
6. Wang D, Hu B, Hu C, et al. Clinical characteristics of 138 hospitalized patients with 2019 novel coronavirus-infected pneumonia in Wuhan, China. *JAMA* 2020. <https://doi.org/10.1001/jama.2020.1585>. Advance Access published on February 7
7. Li Q, Guan X, Wu P, et al. Early transmission dynamics in Wuhan, China, of novel coronavirus-infected pneumonia. *N Engl J Med* 2020. <https://doi.org/10.1056/NEJMoa2001316>. Advance Access published on January 29
8. Chen X, Shang Y, Yao S, Liu R, Liu H. Perioperative care provider's considerations in managing patients with the COVID-19 infections. *Transl Perioper Pain Med* 2020. <https://doi.org/10.31480/2330-4871/116>. Advance Access published on February 12
9. Peng PWH, Ho PL, Hota SS. Outbreak of a new coronavirus: what anaesthetists should know. *Br J Anaesth* 2020. <https://doi.org/10.1016/j.bja.2020.02.008> [Epub ahead of print]

doi: 10.1016/j.bja.2020.02.016